

Case Report

pISSN 2466-1384 · eISSN 2466-1392
Korean J Vet Res 2021;61(2):e15
<https://doi.org/10.14405/kjvr.2021.61.e15>

*Corresponding author:

Jin-Young Chung
Department of Veterinary Internal Medicine
and Institute of Veterinary Science, College
of Veterinary Medicine, Kangwon National
University, 1, Kangwondaehak-gil,
Chuncheon 24341, Korea
Tel: +82-33-250-8656
Fax: +82-33-259-5625
E-mail: jychung77@gmail.com

ORCID:
<https://orcid.org/0000-0001-6729-9834>

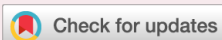†These authors contributed equally to this study.

Conflict of interest:
The authors declare no conflict of interest.

Received: January 15, 2021

Revised: April 19, 2021

Accepted: May 7, 2021



© 2021 The Korean Society of Veterinary Science.

© This is an open-access article distributed under the terms of the Creative Commons Attribution Non-Commercial license (<http://creativecommons.org/licenses/by-nc/4.0/>), which permits unrestricted non-commercial use, distribution, and reproduction in any medium, provided the original work is properly cited.

Motilitone toxicity in a dog

Yoon-Hwan Kim^{1,†}, Jin-Ok Ahn^{1,†}, Yunho Jeong¹, Min Soo Kang²,
Jung Hoon Choi², Jin-Young Chung^{1,*}

¹Department of Veterinary Internal Medicine and Institute of Veterinary Science, College of Veterinary Medicine, Kangwon National University, Chuncheon 24341, Korea

²Department of Veterinary Anatomy and Institute of Veterinary Science, College of Veterinary Medicine, Kangwon National University, Chuncheon 24341, Korea

A three-month-old, intact male Maltese dog was presented to the hospital with lethargy after taking a human medication, Motilitone. Physical examination, including a neurological examination, revealed no remarkable findings, but cholinergic crisis symptoms appeared gradually. Blood and radiological examinations showed no remarkable findings. The dog was tentatively diagnosed with a cholinergic crisis associated with Motilitone intake. Treatment included intravenous administration of atropine (0.02 mg/kg) every 30 minutes and supportive fluid therapy. After 12 hours of treatment, the patient's clinical signs were resolved. This is the first case report describing Motilitone toxicity in a dog.

Keywords: cholinergic crisis; functional dyspepsia; herbal combination; Motilitone; toxicity

Cholinergic crisis refers to a clinical status manifested by the overstimulation of muscarinic or nicotinic receptors at the neuromuscular junction caused by the excessive accumulation of acetylcholine (ACh). The excessive accumulation of ACh is usually caused by the inhibition of the acetylcholinesterase (AChE), an ACh-degrading enzyme [1]. The most common causes are the excessive use of medications for myasthenia gravis or exposure to organophosphates, such as herbicides, insecticides, and other pesticides [1]. The over-accumulation of ACh at the neuromuscular junction causes symptoms related to the muscarinic and nicotinic receptors [1,2]. Clinical findings related to the muscarinic receptors are parasympathetic symptoms, such as miosis, bradycardia, bronchospasm, bronchorrhoea gastrointestinal (GI) secretion, lacrimation, and urination. The symptoms related to the nicotinic receptors are skeletal and respiratory muscular weakness, tachycardia, muscle fasciculation, and flaccid paralysis. Death may result from respiratory compromise and paralysis. The clinical findings also involve stimulation of the central nervous system, resulting in agitation, dullness, seizure, coma, and ataxia [1-3].

Functional dyspepsia (FD) is a complex of symptoms recognized as discomfort in the upper abdomen and includes recurrent upper abdominal pain, excessive fullness, and bloating [4,5]. Drugs, such as metoclopramide, a dopamine antagonist 1st generation drug, domperidone, a dopamine antagonist 2nd generation drug, and cisapride, a serotonin agonist 3rd generation drug, were developed to treat FD [5]. However, several side effects of the drugs have been reported [4].

Motilitone was developed in Korea in 2011 as a 4th generation human FD treatment and was formulated as a combination of *Corydalis Tuber* (the root of *Corydalis yanhusuo*) and *Pharbitidis Semen* (the seed of *Pharbitis nil*). Motilitone's ac-

tivity mechanism has been revealed through many studies. Its gastric fundus relaxation effect appears to be related to the increased gastric compacity by 5-HT_{1A} agonism [4], whereas its visceral analgesic effect appears to be related to the antinociceptive effect of visceral stimuli through adrenergic α_2 agonism [5]. Dopamine causes inhibition of GI motility, but Motilitone is a D₂ antagonist that promotes GI motile functions [6]. In addition, Motilitone's 5-HT₄ agonism is related to the enhanced GI motility and visceral analgesia [5].

To the best of our knowledge, there are no reports on the effect of Motilitone in veterinary medicine. This case study describes the management of a cholinergic crisis in a young dog that consumed Motilitone, which induces parasympathetic activity.

A three-month-old, intact male 1.3 kg Maltese dog was presented to the Veterinary Teaching Hospital of Kangwon National University with lethargy after consuming Motilitone (Motilitone pill form; Dong-A Pharm. Co., Ltd., Korea). Physical and neurological examinations revealed no remarkable findings on the first visit. However, over time, the dog's heart rate decreased (bradycardia), postural reflexes decreased, and the cranial nerve response gradually weakened. Other clinical symptoms, such as pinpoint miosis, salivation, tachypnea, and persistent vocalization, were also presented. Blood and radiological examinations showed no remarkable findings. The dog was diagnosed tentatively with acute cholinergic crisis based on the history and the symptoms related to the enhanced parasympathetics. Treatment started with stabilization of the airway, breathing, and circulation. Oxygen supplementation, warming, and supportive intravenous (IV) fluid therapy (0.9% NaCl) were provided. To overcome the cholinergic crisis, atropine administration was performed. After the first 0.04 mg/kg IV atropine bolus administration, 0.02 mg/kg IV atropine was administered at 30-minute intervals, six times, until no cholinergic crisis-related symptoms were detected. During treatment, the patient's vitals were monitored in real-time. No side effects from atropine, such as tachycardia or mydriasis, were induced. Twelve hours after the first atropine treatment, most of the clinical symptoms had improved, and the patient left the hospital in a healthy state one day after treatment.

For a definitive diagnosis, the concentrations of free ACh and prolactin in the patient's serum and that of four healthy male young (1-3 years) dogs were measured and compared. Client consent to testing the serum of all of the study dogs was obtained. All experimental protocols in this study were based on ethical procedures and were approved by the Kangwon National University Institutional Animal Care and Use Committee

(approval number: KW-201117-1).

The levels of free ACh [7] and prolactin [8] in the serum were estimated using ELISA kits (MBS011705 for free ACh, MBS2604244 for prolactin; MyBioSource, Inc., USA). For ELISA, the serum dilution factors were 1:100 in the ACh ELISA and 1:1 in the prolactin ELISA. All ELISA procedures were conducted according to the manufacturer's instructions. Upon completion of the ELISA procedures, the plate wells were read at 450 nm using a SpectraMax ABS Plus Microplate Reader (Molecular Devices, LLC, USA). Serum was obtained from four healthy dogs, and the average free ACh level was 20.969 ± 9.903 nmol/L in healthy dogs. Before treatment, the patient's ACh level was 31.771 nmol/L, which was higher than the healthy group average. Twelve hours after treatment, the patient's ACh level was 23.903 nmol/L. Twenty-four hours after treatment, the patient's ACh level was 19.391 nmol/L, which was similar to the average level of the healthy group (Fig. 1).

The average prolactin concentration in the four healthy dogs was 2.383 ± 0.323 ng/mL. Before treatment, the patient's prolactin level was 2.811 ng/mL, which was higher than the average of the healthy group. Twelve hours after treatment, the patient's prolactin level was 2.684 ng/mL. Twenty-four hours after treatment, the level was 2.311 ng/mL, which was similar to the average level of the healthy group (Fig. 2).

Motilitone is a widely used botanical drug for treating FD in humans in Korea and is made from *Corydalis Tuber* and *Pharbitidis Semen*. Both of those materials have been used traditionally in Korea, China, and Japan for digestive diseases.

Previous studies have shown that *Corydalis Tuber* and *Pharbitidis Semen*, the raw materials of Motilitone, have AChE inhibition effects [9,10]. The suppression of AChE results in the accumulation of ACh in the brain and other tissues, and it may appear in blood [11].

Dopamine is a hormone that suppresses the secretion of prolactin. Therefore, the action of Motilitone as a D₂ receptor antagonist can lead to hyperprolactinemia. Kwon and Son [5] examine blood prolactin levels after the oral administration of Motilitone and reported that the concentration of prolactin in the blood increased with an increasing drug dosage in rats.

The present study confirmed that Motilitone caused an initial increase in ACh and prolactin in the patient's blood followed by decreases in the concentrations of ACh and prolactin over time. Based on the results of this study, a diagnosis of a cholinergic crisis caused by Motilitone toxicity was made. The diagnosis was supported by the evidence of Motilitone poisoning obtained by measuring the serum concentrations of ACh and prolactin.

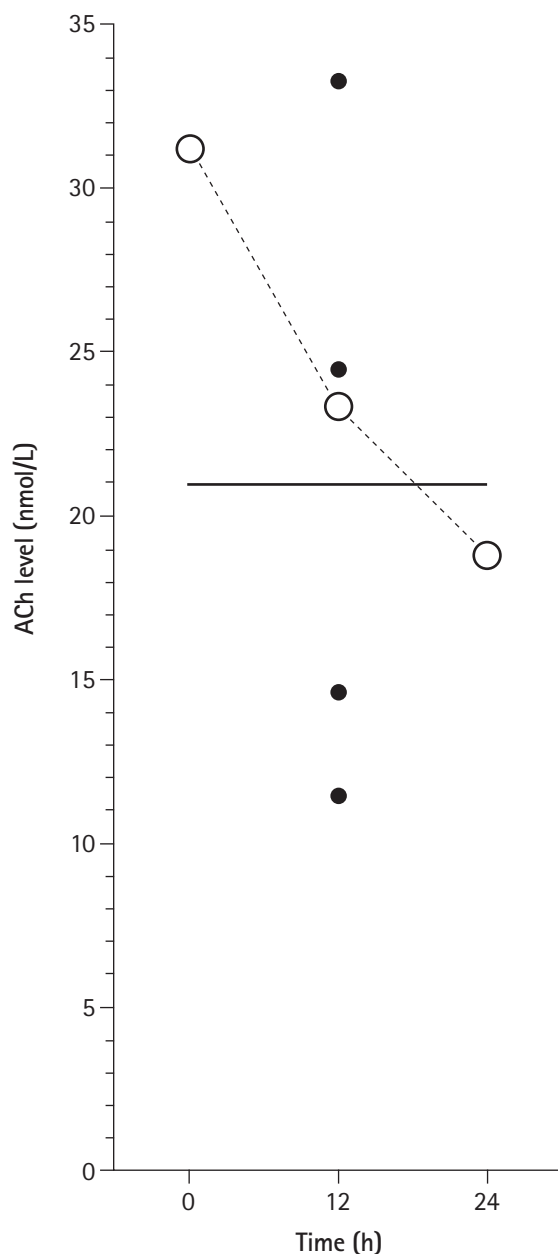


Fig. 1. Serum acetylcholine (ACh) levels in healthy dogs and the patient. The level of ACh in 4 healthy dogs (closed dots) was 20.969 ± 9.903 nmol/L. The blank circles represent the changes over time (0, 12, and 24 hours after treatment) in the patient's ACh level. Before treatment, the ACh level of the patient (31.771 nmol/L) was higher than the average of the healthy dogs. The level decreased with continued treatment (23.903 nmol/L at 12 hours after treatment) and was similar to the average level of healthy dogs after 24 hours (19.391 nmol/L).

Several studies have examined the effects of Motilitone in animal models. A gastric prokinetic effect was observed in rats [12] and dogs [12,13], a gastric relaxation effect was confirmed in dogs [6,12] and rats [4,6], and a visceral analgesic effect was

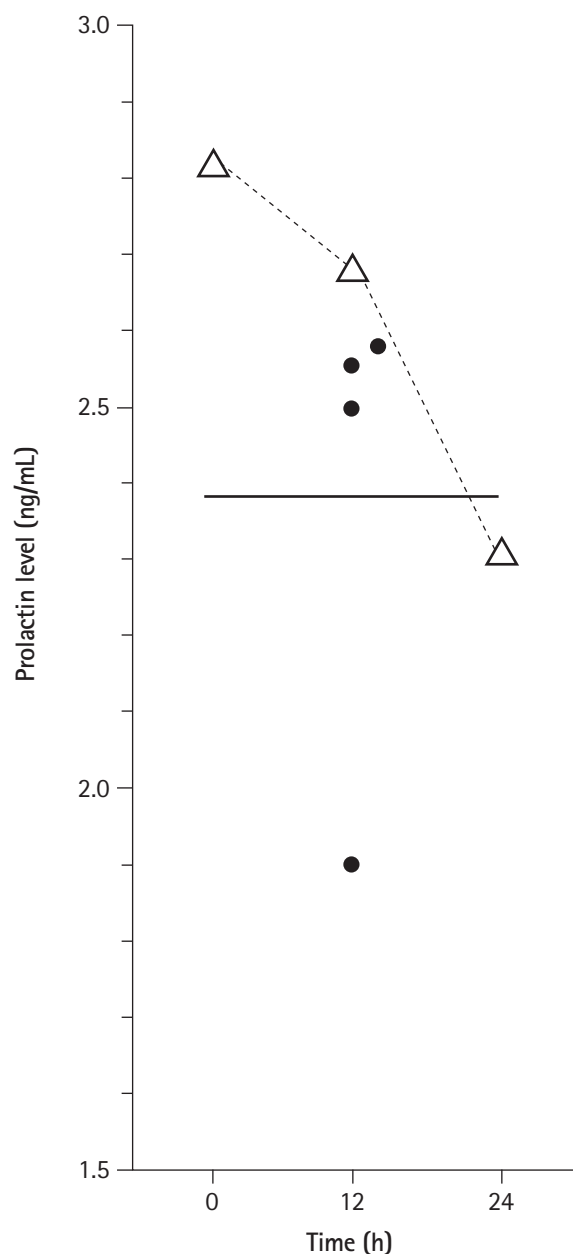


Fig. 2. Serum prolactin levels in healthy dogs and the patient. The prolactin level in 4 healthy dogs (closed dots) was 2.383 ± 0.323 ng/mL. The triangles indicate the changes over time (0, 12, and 24 hours after treatment) in the patient's prolactin level. Before treatment, the prolactin level of the patient was higher than the average of the healthy dogs (2.811 ng/mL). The level decreased with continued treatment (2.684 ng/mL at 12 hours after treatment) and was similar to the average level of healthy dogs after 24 hours (2.311 ng/mL).

demonstrated in rats [14]. Various doses have been applied in studies evaluating the efficacy of FD treatments through animal models. In the reported studies, doses of 0.03 to 10 mg/kg orally (PO) in rats and 0.1 to 3 mg/kg PO in dogs were used, and no

side effects were observed. The Motilitone manufacturer (Dong-A Pharm. Co., Ltd.) reported that after repeated administration for 26 weeks in rats, the no observable adverse effect level (NOAEL) was 150 mg/kg and the LD50 (lethal dose 50%) was greater than 2,000 mg/kg as a single administration in rats. In dogs, it was reported that the NOAEL was 100 mg/kg/day when administered repeatedly for 13 weeks and 200 mg/kg/day with repeated administration for 26 weeks [4]. In this study's patient, the ingested dose was approximately 46 mg/kg, which is less than that reported in a previous toxicity study. On the other hand, considering the patient's age-related metabolic function status, it was presumed that the injected dose was sufficiently toxic. Additional veterinary safety, toxicity, and dosage studies of Motilitone should be undertaken.

The possible treatment options for a cholinergic crisis are administering anticholinergic drugs, such as atropine, catecholamines, such as dopamine, dobutamine, noradrenaline, and adrenaline, or performing hemodialysis or mechanical ventilation in the case of inhaled gases [1,3]. Atropine is an anti-muscarinic anticholinergic drug that competes with ACh on post-synaptic muscarinic receptors and is used widely to treat cholinergic crisis in human medicine [3,15]. In this patient, atropine was administered along with supportive care, with the atropine dosage based on the occurrence of organophosphate poisoning and in accord with the clinical signs [15].

Cholinergic crisis is a life-threatening condition that rarely occurs in human and veterinary fields. This case study is the first report of a cholinergic crisis in a young dog that occurred after taking Motilitone, a human FD medication.

Acknowledgments

This work was supported by Basic Science Research Program through the National Research Foundation of Korea (NRF) funded by the Ministry of Science (NRF-2020R1F1A1073007).

ORCID

Yoon-Hwan Kim, <https://orcid.org/0000-0002-0727-9927>

Jin-Ok Ahn, <https://orcid.org/0000-0002-3300-6084>

Yunho Jeong, <https://orcid.org/0000-0001-9445-3606>

Min Soo Kang, <https://orcid.org/0000-0002-1698-9445>

Jung Hoon Choi, <https://orcid.org/0000-0002-3725-4907>

Jin-Young Chung, <https://orcid.org/0000-0001-6729-9834>

References

1. Adeyinka A, Kondamudi NP. Cholinergic crisis [Internet]. StatPearls Publishing, Treasure Island (FL), 2021 Jan [updated 2021 Feb 26; cited 2021 Apr 17]. Available from: <https://www.ncbi.nlm.nih.gov/books/NBK482433/>.
2. Foy DS, Trepanier LA, Shelton GD. Cholinergic crisis after neostigmine administration in a dog with acquired focal myasthenia gravis. *J Vet Emerg Crit Care (San Antonio)* 2011;21:547-551.
3. Ohbe H, Jo T, Matsui H, Fushimi K, Yasunaga H. Cholinergic crisis caused by cholinesterase inhibitors: a retrospective nationwide database study. *J Med Toxicol* 2018;14:237-241.
4. Jin M, Son M. DA-9701 (Motilitone): A multi-targeting botanical drug for the treatment of functional dyspepsia. *Int J Mol Sci* 2018;19:4035.
5. Kwon YS, Son M. DA-9701: A new multi-acting drug for the treatment of functional dyspepsia. *Biomol Ther (Seoul)* 2013;21:181-189.
6. Lee TH, Kim KH, Lee SO, Lee KR, Son M, Jin M. Tetrahydroberberine, an isoquinoline alkaloid isolated from *corydalis tuber*, enhances gastrointestinal motor function. *J Pharmacol Exp Ther* 2011;338:917-924.
7. Sarasamma S, Audira G, Juniardi S, Sampurna BP, Liang ST, Hao E, Lai YH, Hsiao CD. Zinc chloride exposure inhibits brain acetylcholine levels, produces neurotoxic signatures, and diminishes memory and motor activities in adult zebrafish. *Int J Mol Sci* 2018;19:3195.
8. Gutiérrez J, Gazzano A, Torracca B, Meucci V, Mariti C. Determination of prolactin in canine saliva: is it possible to use a commercial ELISA kit? *Animals (Basel)* 2019;9:418.
9. Lee S, Lee D, Baek J, Jung EB, Baek JY, Lee IK, Jang TS, Kang KS, Kim KH. In vitro assessment of selected Korean plants for antioxidant and antiacetylcholinesterase activities. *Pharm Biol* 2017;55:2205-2210.
10. Xiao HT, Peng J, Liang Y, Yang J, Bai X, Hao XY, Yang FM, Sun QY. Acetylcholinesterase inhibitors from *Corydalis yanhusuo*. *Nat Prod Res* 2011;25:1418-1422.
11. Stewart WC. Accumulation of acetylcholine in brain and blood of animals poisoned with cholinesterase inhibitors. *Br J Pharmacol Chemother* 1952;7:270-276.
12. Lee TH, Choi JJ, Kim DH, Choi S, Lee KR, Son M, Jin M. Gastroprokinetic effects of DA-9701, a new prokinetic agent formulated with *Pharbitis Semen* and *Corydalis Tuber*. *Phyto-medicine* 2008;15:836-843.
13. Kim ER, Min BH, Lee SO, Lee TH, Son M, Rhee PL. Effects of DA-9701, a novel prokinetic agent, on gastric accommodation

- in conscious dogs. *J Gastroenterol Hepatol* 2012;27:766-772.
14. Kim ER, Min BH, Lee TH, Son M, Rhee PL. Effect of DA-9701 on colorectal distension-induced visceral hypersensitivity in a rat model. *Gut Liver* 2014;8:388-393.
 15. Plumb DC. *Plumb's Veterinary Drug Handbook*. 9th ed. Wiley-Blackwell, Chichester, 2018.